

Intra Thoracic Extra Pulmonary Supra Apical Tuberculoma in Pott's Disease: A Case Report and Review of Literatures

Pratap Chandra Nath,
Manmath Kumar Dhir,
Soubhagya Ranjan Tripathy
and Somnath Prasad Jena

Department of Neurosurgery, SCB
Medical College, Cuttack, Odisha, India

Abstract

Background: Spinal tuberculosis is one of the commonest forms of skeletal tuberculosis in India. It accounts for about 50% of osteo-articular tuberculosis. Spinal tuberculosis causes significant morbidity in Indian Population. Often patients present with Pott's disease related paraplegia attended by "destruction of vertebral body, lamina, pedicle and spinous process with perivertebral abscess". Huge intra-thoracic extra-pulmonary extra-plural supra- apical tuberculoma due to extension of spinal tuberculosis is not reported yet. We describe here such a case of complete paraplegia with huge chest mass and its successful management.

Case description: A 20 years young male presented with upper thoracic Pott's paraplegia showing involvement of D1-D3 vertebra with their left pedicle, part of lamina, costo-vertebral and costo-transverse joint with a huge intra thoracic extra-pulmonary supra apical granular tuberculoma mimicking apical tumor. The patient was managed by a posterior "T" shaped vertical midline approach with debridement and decompression of spinal cord and excision of intra thoracic supra apical tuberculoma extra-pleurally. He was administered ATT perioperatively. Postoperatively he followed up for 1 year and now able to walk, run and play normally as before.

Conclusion: Pott's spine may present with intra-thoracic extra-pleural mass which can be managed by posterior costo-transversectomy and laminectomy. So proper assessment of disease and early need full surgical intervention with anti-tubercular therapy can control severe morbidity and disability.

Keywords: Spinal tuberculosis; Intra-thoracic; Extra-pulmonary; Supra-apical; Mimicking pancoast tumor

Abbreviations: D: Thoracic; C: Cervical; MRI: Magnetic Resonance Imaging; CT: Computed Tomography; FNAC: Fine Needle Aspiration Cytology; ATT: Anti Tubercular Therapy; TB: Tuberculosis

Corresponding author:

Dr. Pratap Chandra Nath

✉ drpratapnath@rediffmail.com
drpratapnathmama@gmail.com

M.Ch. Trainee, Department of Neurosurgery,
SCB Medical College, Cuttack, Odisha, India.

Tel: +91 9437782184

Citation: Nath PC, Dhir MK, Tripathy SR, et al.
Intra Thoracic Extra Pulmonary Supra Apical
Tuberculoma in Pott's Disease: A Case Report
and Review of Literatures. Neurosurg. 2016, 2:1.

Received: December 29 2015; **Accepted:** January 22, 2016; **Published:** January 29, 2016

Introduction

Spinal tuberculosis is the commonest form of skeletal tuberculosis accounting for about 50% of osteo articular tuberculosis [1]. Spinal tuberculosis is a common infectious disease found in developing countries like India. Often patients present with Pott's disease related paraplegia attended by "destruction of vertebral body,

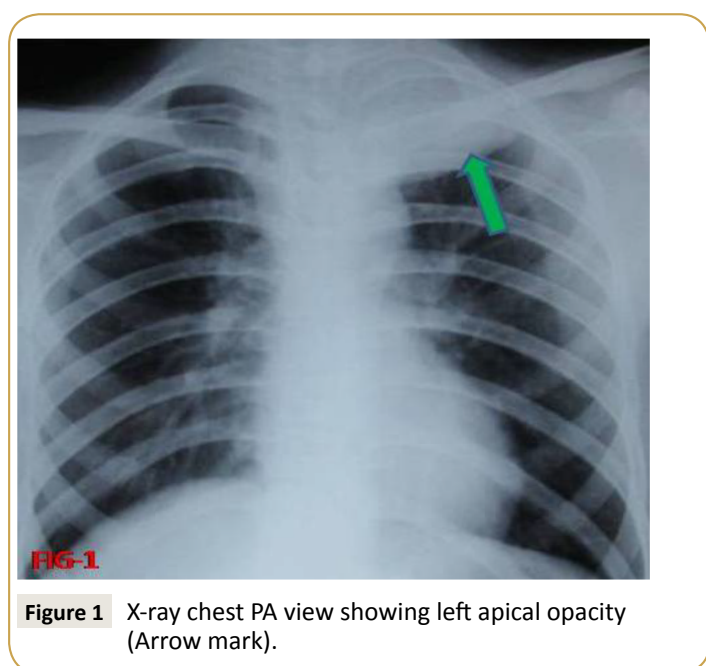
lamina, pedicle and spinous process with perivertebral abscess" Intra extra-plural supra-apical thoracic extension of spinal tuberculosis is not previously reported. We report here a case of Pott's paraplegia and a huge intra thoracic extra-pulmonary supra apical granular tuberculoma mimicking apical tumor with its successful management.

Case Reports

Case description and neurological examination

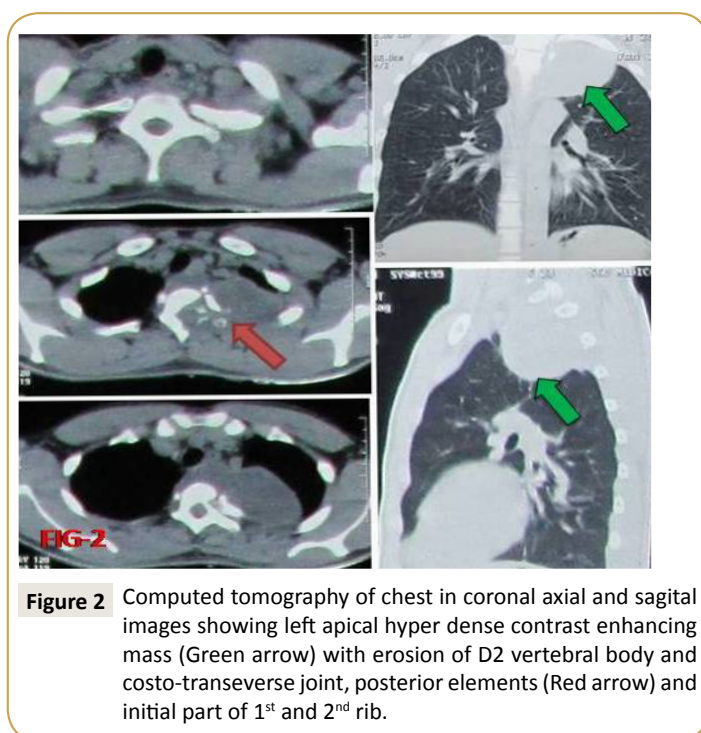
A 20 year young male presented with bilateral lower limb weakness for 1 ½ months which progressed to complete spastic paraplegia and bedridden after 15 days of onset. He had history of intermittent fever since last 4 months with loss of weight and appetite. On neurological examination he had grade-0/5 (Medical Research Council) power in his both lower limb with exaggerated bilateral deep tendon reflexes and extensor plantar response. There was graded decrease in all modalities of sensation at T4 dermatome and below. There was no involvement of bowel and bladder. There was no history of any trauma to spine, recent vaccination, and had no spinal deformity and no gibbous except mild tenderness in the upper thoracic region and had no lymphadenopathy.

A chest radiograph revealed erosion of 2nd left costo-vertebral joint with erosion of 2-3 cm of 2nd rib with a huge opacities in the left apical region of lung with slight midline shift towards right (**Figure 1**). CT chest revealed left apical hyper dense lesion with left sided partial erosion of D1 and D2 vertebral body and D1 costo-transverse joint and adjacent part of 1st and 2nd rib (**Figure 2**). His blood parameters showed haemoglobin-10 gms/dl, ESR-12 at 1st hour, total leukocytes count -7,400, differential count-L-30% and N-63% and 72 hours Montoux test was not significant. MRI revealed compression of spinal cord from D1 to D3 level mostly in its left ventral aspects with prevertebral and left paravertebral T1 weighted - hypo intense, T2-weighted hyper intense heterogeneously enhancing lesion indicating spinal Koch's sequel (**Figure 3**). D1-D3 vertebral bodies show T1 hypo intense, T2 intermediate signal alteration with variable inhomogeneous enhancement. We planned for CT guided fine needle aspiration cytology of chest mass to exclude any malignant pathology which revealed Langhan's giant cell, epithelioid cells, and necrosis without any malignant cells suggestive of tuberculosis.



Management

On diagnosis of tuberculoma on CT guided FNAC we started 4 drug regimen anti-tubercular therapies. Though anti tubercular were administered preoperatively, due to huge mass lesion and paraplegia in this young male we preferred surgical decompression. A posterior approach with "T" incision comprising midline skin incision from C 7-D 5 with an adjoining transverse incision along the 3rd intercostals space was done. After paraspinal muscles were dissected, around 2 cm of 2nd rib with transverse process and part of lamina were found eroded and sequestered with exposure of cord. The paravertebral abscess extending to chest wall opened up with gussing out of around 300 ml of exudative granulomatous turbid fluid and flakes. The most importantly and the interesting part of surgery was excision and debridement of intra thoracic supra-apical extra-plural solid cystic granuloma of size of 8 x 6 x 4 cm (**Figure 4A**). The granulomatous tissues adhered to pleura were dissected meticulously without breaching the pleura. The part densely adhered impending plural breach were left as such. With gradual decompression lung inspiratory pulsation were visualized and there was also some expansion of compressed apical portion of lung. The partially eroded lamina and costo-transverse joint of 3rd vertebrae is excised. The D1 lamina under cutting was done to release the cord. The granulation tissue adhered over the cord are dissected out. CSF flow was established. The wound closed in layer with the drain in supra apical area in a non-dependent pattern. The squash cytology and exudative fluid analysis were in favor of tuberculosis. Post-operative X-ray was done with drain in situ showed expanded lung with minimal apical opacities. The drain was taken out on 2nd day after X-ray (**Figure 4B**). On immediate 1st post-operative day the patient improved to grade 2/5 with sensory improvement. At time of discharge on 7th post operative day, he had bilateral lower limb power of 3/5. During 1st



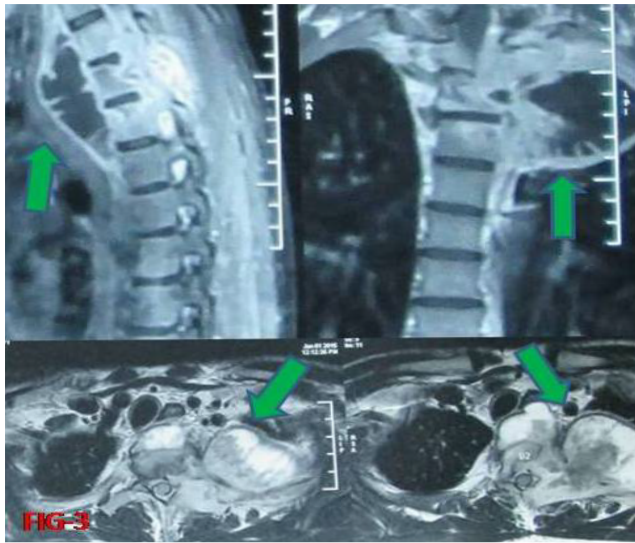


Figure 3 Magnetic resonance imaging of cervicothoracic region in sagittal, coronal and axial images showing in homogenous septet intrathoracic supra apical mass lesion with paravertebral abscess.

follow up at one month he improved significantly and was able to walk without support. On 2nd follow up at 3rd month, his chest radiograph showed absolutely bilateral normal lungs with spinal bony defects and he improved and walk without support rapidly from first visit. Now during the time of reporting at 1 year he is able to run, play and doing his study life as before.

Discussion

Vertebral tuberculosis is the commonest form of skeletal tuberculosis accounting for about 50 % of osteo-articular tuberculosis [1]. Spinal TB can occur at any age and most common in the first three decade of life. Spinal tuberculosis presents variably and produces variety of presentation. Neurological involvement is the dreaded complication and found in 10-30% cases of spinal TB [2]. The spinal TB presents as paraplegia due to different causes like inflammation of surrounding structure, granulation tissue, compression fracture, mass effect of abscess, spinal vascular thrombosis, sequestrum in spinal canal or fibrous scarring of healed TB [3, 4]. The cause of paraplegia in our case is due to granulation tissue and mass effect by the paravertebral abscess on that side due to eroded posterolateral spine.

Tuberculosis mimics a variety of condition including other infectious disease like fungal infection, chronic inflammatory diseases and malignancy. In our case in chest x-ray it showed opacity in left apical region mimicking apical lung malignancy. In MRI presence of paravertebral abscess helps in excluding malignancy but the apical mass creates some diagnostic dilemma. We proceeded for CT guided FNAC to exclude the malignancy. Gupta RK et al. described that presence of an abscess and bone fragments differentiate spinal tuberculosis from neoplasia and if there is any doubt, an image guided biopsy is indicated [5].

Differential diagnosis from other conditions that can be located in the apex of the chest should be made. These conditions include

tumors (pan cost tumor, primary chest wall and metastatic tumors, pleural mesothelioma), infectious and inflammatory lung diseases (tuberculosis, aspergillosis, echinococcus, actinomyces and lung abscesses from common bacteria, inflammatory pseudo tumor) that can invade and destruct the apical bony skeleton of the thorax. The lesion was mimicking as pancoast tumor in X-ray signs and symptoms of malignancy like loss of weight, loss of appetite etc. CT thorax, CT guided FNAC and MRI excludes the malignancy. According to Christophoros N et al. CT guided FNAC/B should always be to before initiation of treatment in a case of opacity seen in x-ray at apical region [6].

Extension of spinal tuberculosis with paravertebral abscess into adjacent pleura, lymph node and retroperitoneal space, production of psoas abscess are reported in literatures [7, 8]. But this type of typical extra pulmonary, extra plural supra apical intrathoracic involvement is not reported yet as per best of our knowledge. Paradiscal spinal TB is the commonest type and usually involved the contiguous area of two adjacent vertebrae along with intervening disc, but in our case it seems to involve left transverse process with adjacent vertebral body giving rise to total involvement of costotransverse and costovertebral joint. The typical feature of TB spine like gibbus is not found in our case. Fungal culture was negative which excludes the diagnostic dilemma of fungal infection. The biopsy report also comes as granulomatous inflammation with excessive caseous necrosis, scattered epithelial cell, epitheloid cell and langerhan's type giant cell suggesting tubercular lesion.

Jain et al also described that Neurologic complications are the most dreaded complication of spinal tuberculosis. The patients who have paraplegia develop in the active stage of tuberculosis of the spine require active treatment for spinal tuberculosis and have a better prognosis than the patients who have paraplegia develop many years after the initial disease has healed. Neurologic dysfunctions in association with active tuberculosis of the spine can be prevented by early diagnosis and prompt treatment. When needed, a combination of conservative therapy and surgical decompression yields successful results in most patients with tuberculosis of the spine to prevent and treat neurologic complication like paraplegia [9, 10]. Though conservative ATT is the commonly practiced treatment but in some cases as in our case combine modalities surgery plus ATT is the most applicable treatment. In our case, patient was administered anti-tubercular drugs preoperatively which decreased the infectivity and elimination of post-operative dissemination of infection. Mostly the patient of developing countries present in very late stage as in our case with paraplegia and huge paravertebral abscess and other adjacent structure involvement. So early surgical decompression should be undertaken to decreases the disability as in our case. As we have done only debridement of the both intra and extra thoracic lesions with decompression of spinal cord without hampering the spinal stability, the post-operative anti-tubercular therapy was continued. In our case there was no need of any stabilization as it was mostly involved the posterolateral aspect of one side only, without involvement of spinous process and inter spinous ligament and vertebral

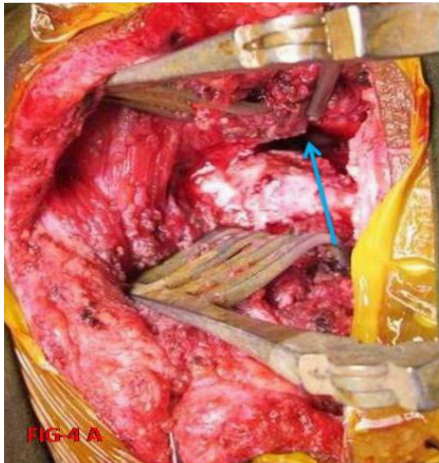


FIG-4 A

Figure 4a Intraoperative image showing pathway to intrathoracic supra apical cavity after debridement of granular mass (Shown by arrow).

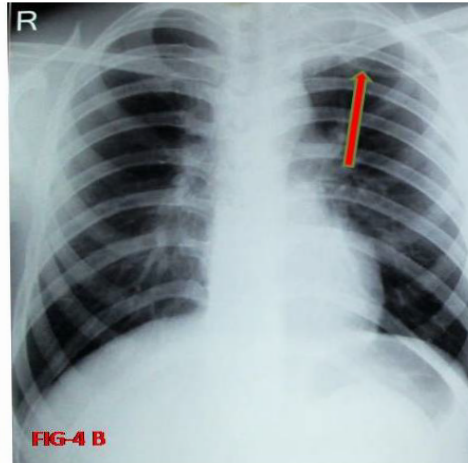


FIG-4 B

Figure 4b Immediate postoperative x-ray chest showing drain in situ and decreased opacity at left apical region (Shown by arrow).

body collapse. The intervertebral discs were not involved. And again thoracic vertebrae are less mobile producing less dynamic instability. Complete paraplegia with bed ridden for a short period of 15 days with combine modality of treatment made the patient cured, because long duration paraplegia has worse prognosis. The patient at the time of discharge on 7th post-operative day had bilateral lower limb power of 3/5. Now during the time of reporting at 1 year he is able to run, play and doing his study life as before. This dramatic improvement got by both surgical decompression and anti-tubercular therapy made this young male devoid of permanent disability due to tuberculosis.

Conclusion

Spinal tuberculosis is a major cause of disability in developing country like India. So proper assessment of disease and need full surgical intervention with anti-tubercular therapy can control severe morbidity and disability. TB spine may present as apical mass and involve many adjacent and distant sites in body mimicking different conditions including malignancy. Proper clinical, radiological and tissue diagnosis is to be made to exclude other conditions.

Conflict of Interest

All authors have none to declare.

References

- 1 Jain AK, Dhammi IK (2007) Tuberculosis of the spine: a review. *Clin Orthop Relat Res* 460: 39-49.
- 2 Tuli SM (1991) Tuberculosis of the spine. *Tuberculosis of skeletal system* (Tuli SM ed) J.P. Brothers New Delhi 132-253.
- 3 Mukhopadhyaya B, Mishra IVK (1987) Tuberculosis of the spine. *Ind J Surg.* 19:59.
- 4 Sankaran-Kutty M, Chowdhary UM, Corea JR, al-Majid MH (1991) The role of computerised tomography in the management of spinal tuberculosis. *Int Orthop* 15: 319-321.
- 5 Gupta RK, Agarwal P, Rastogi H, Kumar S, Phadke RV, et al. (1996) Problems in distinguishing spinal tuberculosis from neoplasia on MRI. *Neuroradiology* 38 Suppl 1: S97-104.
- 6 Christophoros N, Foroulis, Paul Zarogoulidis, Kaid Darwiche, Nikolaos Katsikogiannis, et al. (2013) Superior sulcus (Pancoast) tumors: current evidence on diagnosis and radical Treatment *J Thorac Dis* 5: S342–S358.
- 7 Maron R, Levine D, Dobbs TE, Geisler WM (2006) Two cases of pott disease associated with bilateral psoas abscesses: case report. *Spine (Phila Pa 1976)* 31: E561-564.
- 8 Sathyamoorthy P (1990) Extension of paravertebral abscess in tuberculosis of the thoracic spine: report of two cases. *Med J Malaysia* 45: 329-334.
- 9 Jain AK (2002) Treatment of tuberculosis of the spine with neurologic complications. *Clin Orthop Relat Res*: 75-84.
- 10 Jain AK (2010) Tuberculosis of the spine: a fresh look at an old disease. *J Bone Joint Surg Br* 92: 905-913.