

Meningiomas of the Third Ventricle in Childhood

Ali GENC¹ and
Burcu Kasapoglu²

Keywords: Third ventricle; Pediatric meningiomas; Huge meningiomas; Hydrocephalus; Atypical meningioma; Cerebral salt wasting

Received: March 03, 2016; **Accepted:** April 04, 2016; **Published:** April 11, 2016

Intraventricular meningiomas are rare and relatively more often seen in children. Most often, these arise from the lateral ventricular walls. On the other hand, meningiomas of the third ventricle are extremely unusual and difficult to diagnose [1]. Those meningiomas arising in the third ventricle account for 0,15% of all meningiomas [2] and less than 20 cases have been reported in English literature [2, 3]. These tumors are considered as a subtype of pineal region tumors that arise from the posterior portion of the velum interpositum, the double layer of pia mater that forms the roof of the third ventricle. The origin of these tumors can be traced to embryological invagination of arachnoid cells into the choroid plexus [1, 2]. In this letter we present two cases of huge meningiomas of the third ventricle in pediatric patients, including one atypical meningioma.

Case 1

The first case was a 9 year-old boy who was admitted with a 6 year-history of headache that had worsened and accompanied by nausea and vomiting recently. Neurological examination revealed bilateral papilledema. MRI disclosed a midline tumor located in the third ventricle. It was compressing neighboring tissues and resulting into secondary signal changes in the periventricular white matter. The tumor was causing dilatation of the lateral ventricles and protruding into the dilated lateral ventricles via both foramina of Monroe. The tumor was a multi-lobulated mass with homogeneous enhancement after contrast medium injection. The mass lesion was hypointense on T1 and T2 weighted images and isointense on FLAIR image (Figure 1). A surgical treatment via an anterior interhemispheric transcallosal approach was performed. A stone-hard, pink-gray and well-demarcated tumor was reached through the right ventricle and totally removed. The recovery was uneventful and the patient was discharged without any neurological deficits. Microscopically, the tumor had a mixed pattern combining aspects of meningoepithelial as well as fibrous meningiomas. It consisted of solid lobules of meningoepithelial cells with whorls of spindle-shaped cells and psammoma bodies. The tumor had no mitotic activity or necrosis. Therefore it was considered as typical 'transitional' meningioma.

- 1 Kolan Hospitals, Department of Neurosurgery, Istanbul, Turkey
- 2 Yeditepe University, Department of Genetics, Istanbul, Turkey

Corresponding author: Ali GENC MD

✉ draligenc@gmail.com

MSc, Kolan Hospital Group, Department of Neurosurgery, Kaptanpasa Mh Darulaceze Cd. No14 Okmeydani, 34384 Sisli Istanbul, Turkey.

Tel: 0090-533-2177725, 0090-212-539

Citation: GENC A, Kasapoglu B. Meningiomas of the Third Ventricle in Childhood. *Neurosurg.* 2016, 1:2.

Case 2

The second case was 4 year-old girl who had been suffering from headache, nausea and vomiting for one year. Neurologic examination was significant for a positive Romberg test and bilateral papilledema. The patient had no history of neurofibromatosis in her family, but occasional cafe au lait spots were noted over her trunk but not sufficient for a diagnosis. A cranial MRI revealed a third ventricular mass extending deep into suprasellar region accompanied by triventricular hydrocephalus. The lesion was a lobulated isointense mass on T1W with homogenous enhancement after gadolinium injection, and seemed hypointense on T2W and FLAIR image (Figure 2). An anterior interhemispheric transcallosal approach was planned, due to the tumor's anterior location inside the third ventricle. Similarly the third ventricle was reached through the right ventricle. The tumor was of a stone hard consistency, white to gray in color and had extensive plaque adhesions to left hypothalamic wall of the third ventricle. Total removal was achieved in a piecemeal fashion. Postoperatively, this child developed hyponatremia and repeating epileptic attacks, which were attributed to cerebral salt

wasting syndrome. Hyponatremia was corrected and symptoms disappeared. The patient was discharged with no neurologic deficits. Microscopically, the tumor had a diffuse monotonous meningotheliomatous appearance with moderate pleomorphism and atypia with a high mitotic activity. No psammoma bodies were noted. Small isolated necrotic foci were present. Consequently, the tumor was considered as an atypical meningotheliomatous meningioma (WHO grade II, 2000).

Discussion

Third ventricular meningiomas, as with our cases, generally present with only signs of increased intracranial pressure. Because of the fact that they grow in a naturally existing space, compliance for increases in intracranial pressure is high and the symptoms are subtle. So these tumors can go unnoticed until they become huge. In our cases the tumor sizes approached 6 cm at the foramen of Monroe, leading to dilatation of the lateral ventricle, which will further increase the intracranial pressure. In this stage patients generally present with headache, nausea

and vomiting. Papilledema is usually evident on neurological examination. Rarely patients may present with ptosis, nystagmus, gait disturbances, seizures, visual disturbances, polyuria and polydipsia. MRI should be the choice of diagnostic procedure. The tumor appears hypointense on T1-weighted images and enhances homogenously after contrast administration. As in our case 2, heterogeneous appearance due to necrotic foci may suggest the aggressiveness of the tumor. The anatomic details are very well documented and the surgical strategy can easily be determined. Also MR angiography can offer the additional benefit of demonstrating the vascular supply of the tumor. Surgery is the definitive treatment for these tumors [4]. Histologically, as anywhere else in the nervous system, most intraventricular meningiomas are benign. However, previous reports show that third ventricle meningiomas have a noticeable propensity to display atypical histology [3]. Therefore, such patients should be closely followed up for recurrences of the tumor even after total surgical removals.

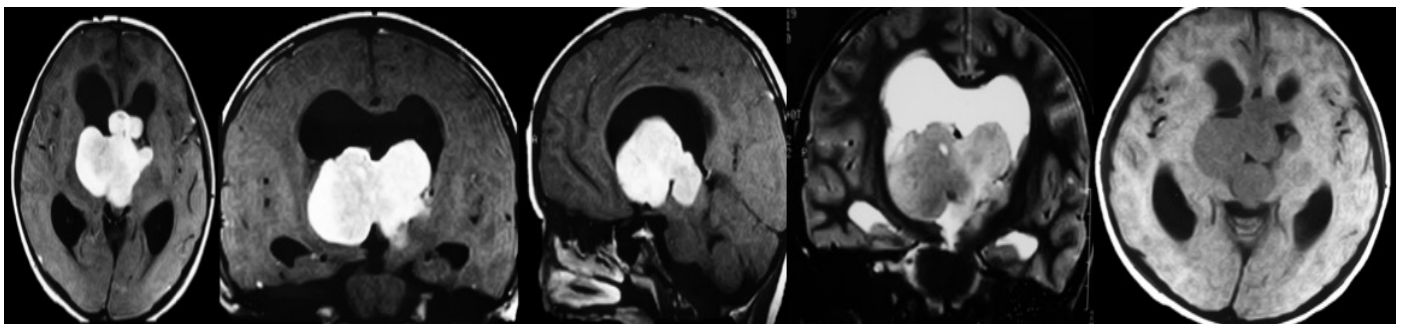


Figure 1 MRI study of Case 1; preoperative axial, coronal and sagittal T1W images showing homogenous enhancement after gadolinium injection. Coronal T2W and axial flair images show no periventricular passage of cerebrospinal fluid(CSF) despite prominent hydrocephalus.

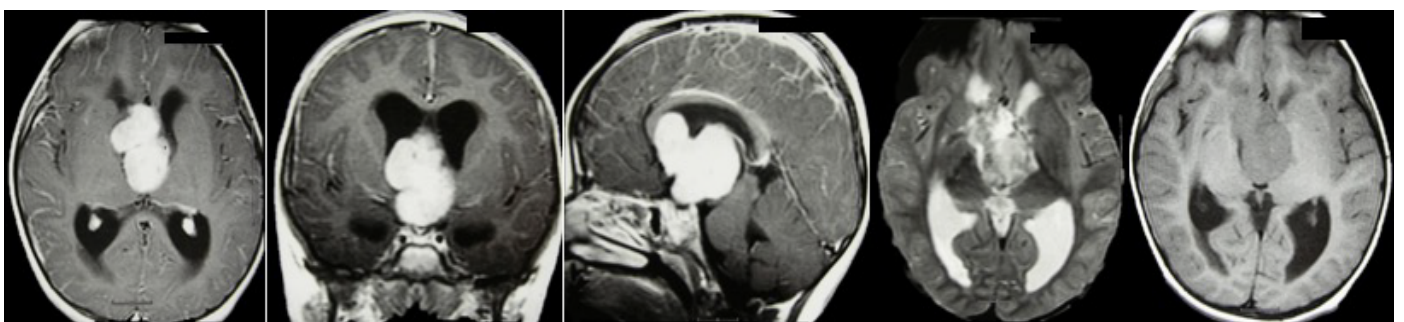


Figure 2 MRI study of Case 2; preoperative axial, coronal and sagittal T1W images showing a lobulated huge mass homogenous enhancement after gadolinium injection with compression of venous structures as well as ventricular dilatation. Axial T2W image shows a heterogeneous hypointense mass while axial flair images reveal isointensity of the mass with no periventricular passage of CSF.

References

- 1 Moiyadi AV, Shetty P (2012) Giant velum interpositum meningioma in a child. *Indian J Med Paediatr Oncol* 33: 173-175.
- 2 Uygur ER, Deniz B, Zafer K (2008) Anterior third ventricle meningiomas. Report of two cases. *Neurocirugía* 19: 356-360.
- 3 Karki P, Yonezawa H, Bohara M, Oyoshi T, Hirano H, et al. (2015) Third ventricular atypical meningioma which recurred with further malignant progression. *Brain tumor pathology* 32: 56-60.
- 4 Li P, Diao X, Bi Z, Hao S, Ren X, et al. (2015) Third ventricular meningiomas. *Journal of clinical neuroscience* 22: 1776-1784.